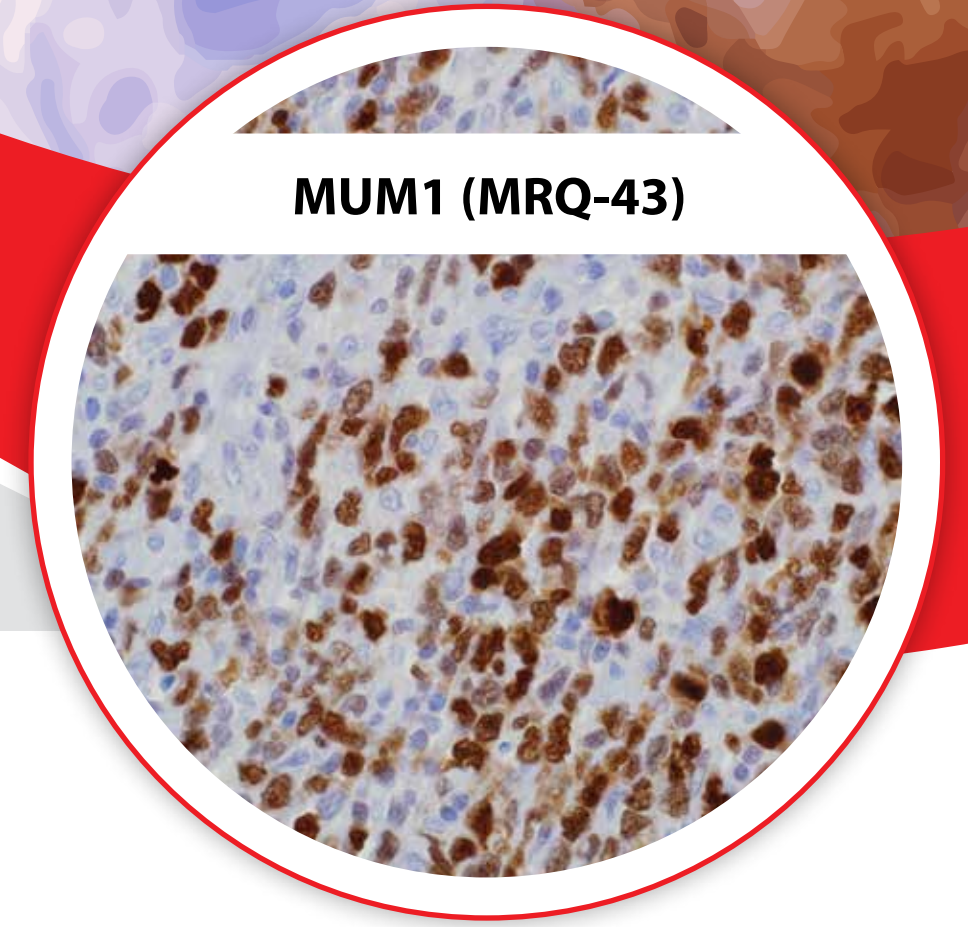


# Mature B- and T-cell Lymphomas and Leukemias

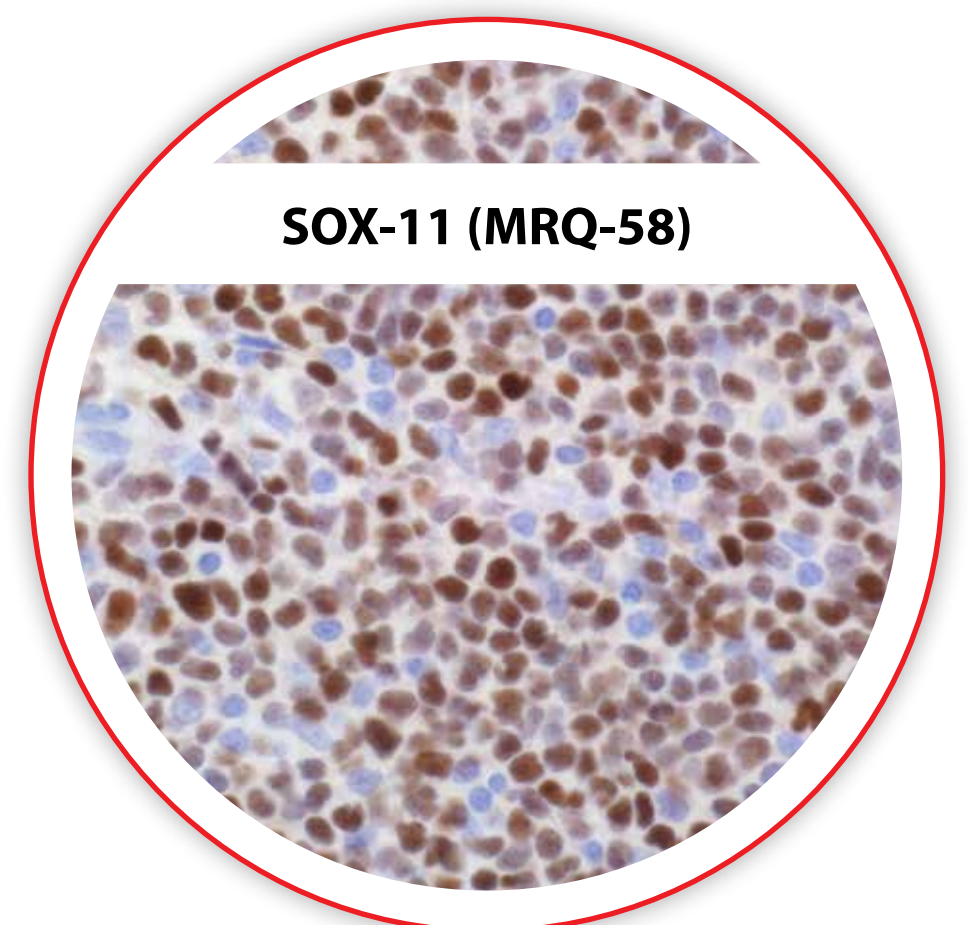
Lymphomas and leukemias are derived from hematopoietic and hemolymphoid system cellular elements distributed throughout the body. Many different classifications of hematopoietic and hemolymphoid neoplasms have evolved over the years, resulting in the utilization of various techniques including immunohistochemistry, flow cytometry, and molecular/genetic studies. These tables are based on the most recent WHO classification (2008). This collection of tables represents an effort to tabulate useful information regarding the general reactivities of the specified antibodies in the respective mature B- and T-cell lymphomas and leukemias as listed. It must be kept in mind that these tables are in no way a substitute for knowledge of the literature with respect to a particular clone or polyclonal product; these tables represent results of a collation of the literature available to us at the time of preparation. Individual results within laboratories may vary somewhat as techniques and protocols are pertinent variables. It is the hope of Cell Marque that pathologists and laboratorians, in general, will find these useful in daily pathology practice when it comes to making differential diagnosis for patients in this somewhat complicated and evolving area of study.

*Michelle Lacey, M.D.*



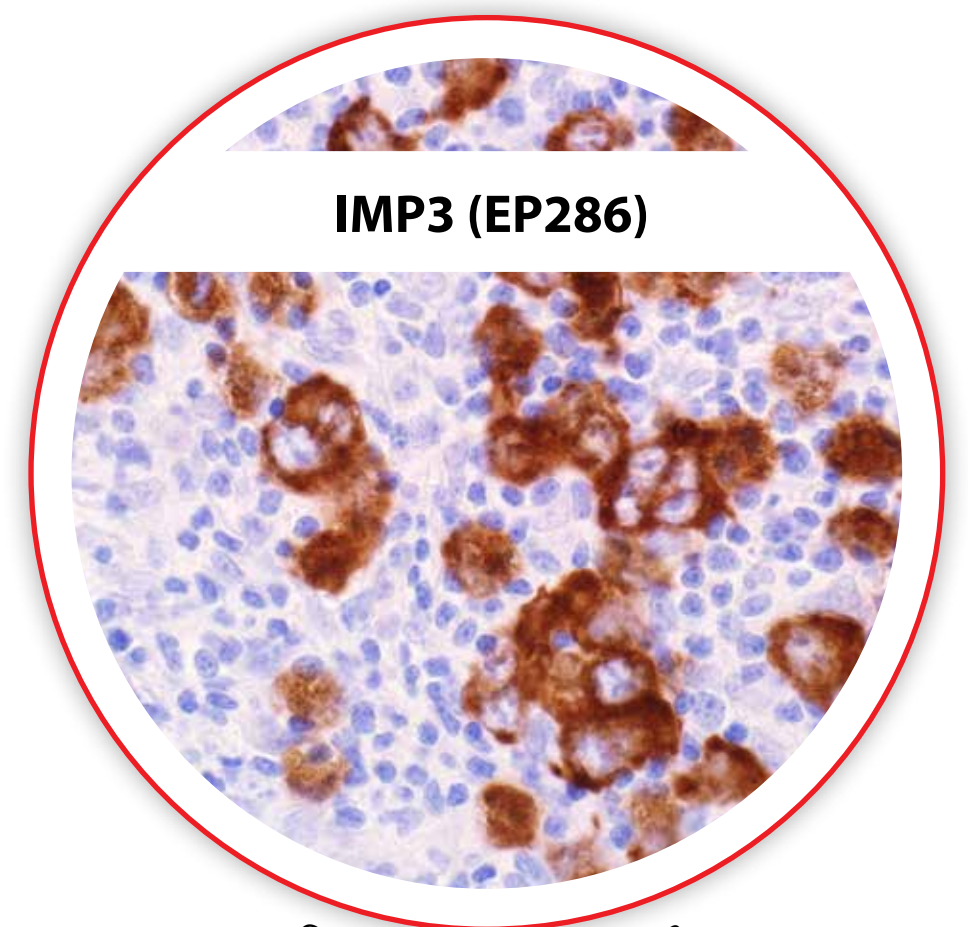
**MUM1 (MRQ-43)**

DLBCL



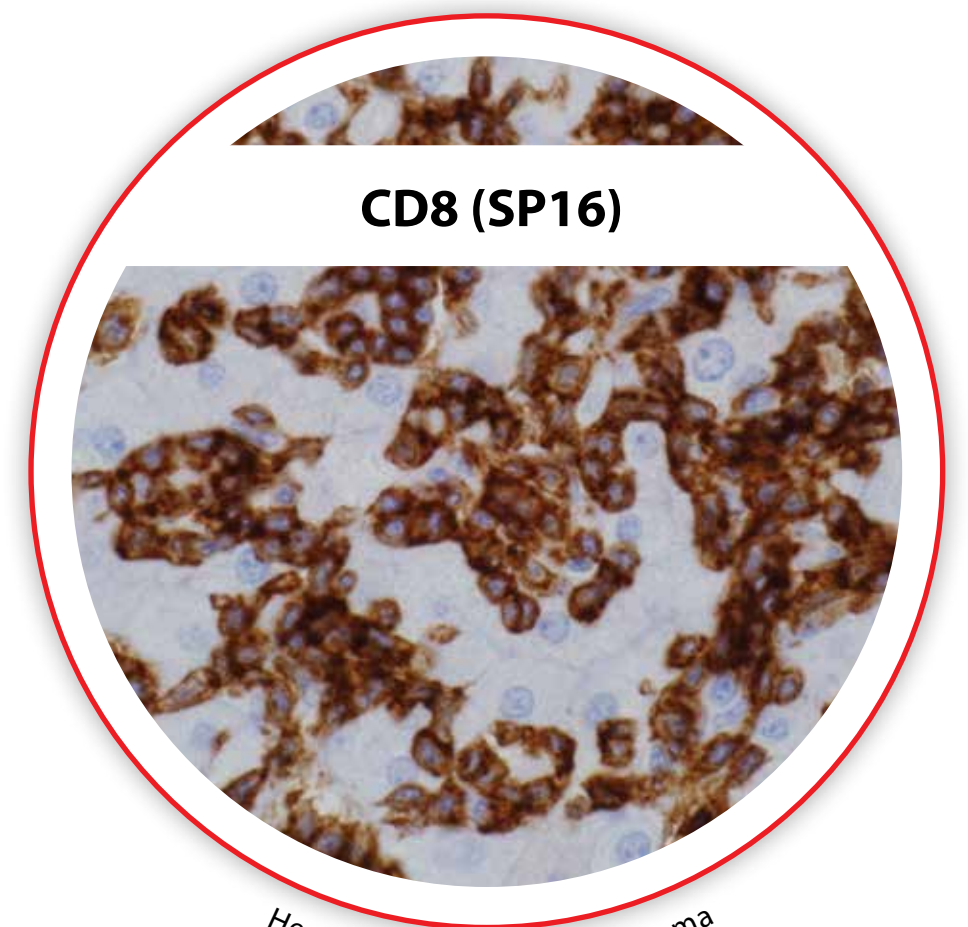
**SOX-11 (MRQ-58)**

Mantle Cell Lymphoma



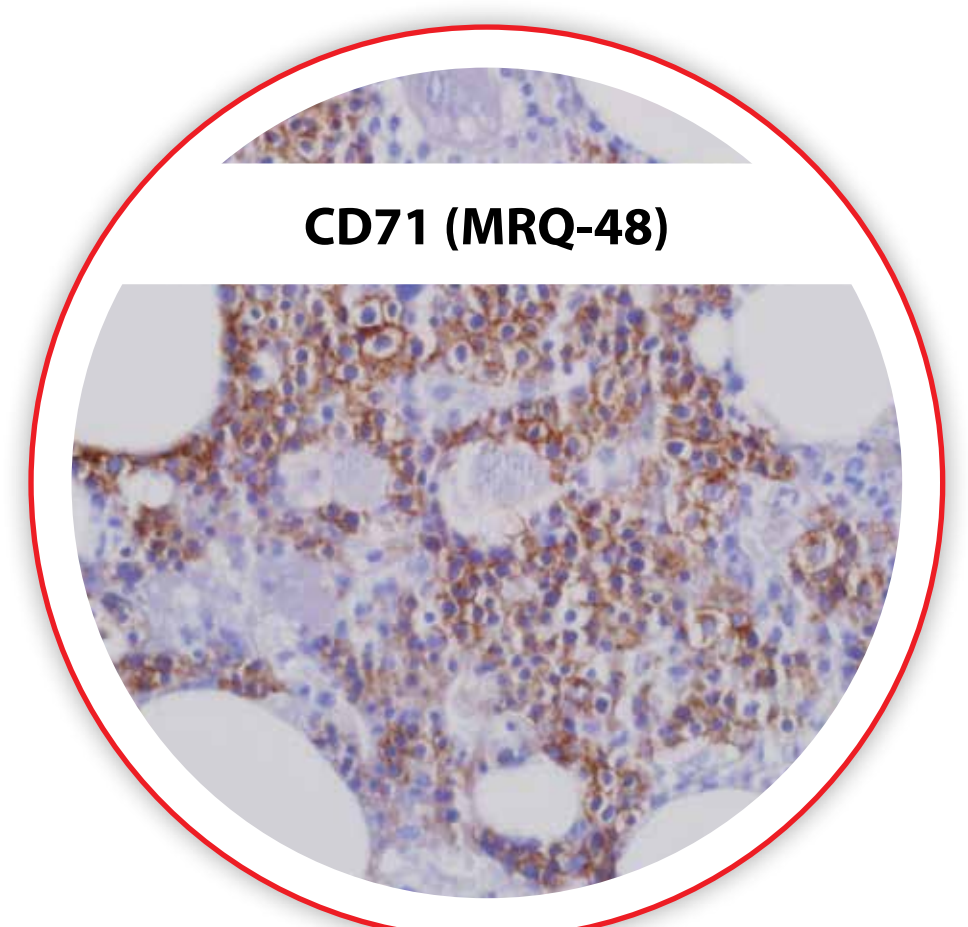
**IMP3 (EP286)**

Classic Hodgkin Lymphoma



**CD8 (SP16)**

Hepatosplenic T-cell Lymphoma



**CD71 (MRQ-48)**

Erythroid Hyperplasia

Mature B-Cell Lymphomas	CD45	CD20	CD79a	CD10	CD5	CD23	CD43	CD30	BCL2	BCL6	Cyclin D1	PAX-5	BOB.1	Oct-2	MUM1	CD25	TRAcP	Annexin A1	TCL1	T-bet	IgD	c-Myc	Ki-67	SOX-11	EBV
Chronic Lymphocytic Leukemia/ Small Lymphocytic Lymphoma	+	+	+	-	+	+	+	-	+	-	-	+	+	+	+	-	-	-	+	+	+	-	Low	-	
Follicular Lymphoma	+	+	+	+	-	-	-	-	+	+	-	+			-/+					+	-	+	-	Low	-
Mantle Cell Lymphoma	+	+	+	-	+	-	+	-	+	-	+	+			+				+	-	+	-	+		
Splenic Marginal Zone Lymphoma	+	+	+	-	-	-	-	-	+	-	-	+			-	-	-	-	-	+	-/+	-	Low	-	
Nodal Marginal Zone Lymphoma	+	+	+	-	-	-	+	-	+	-	-	+			-	-	-	-	-	+	-/+	-	Low	-	
Extranodal Marginal Zone Lymphoma/Mucosal Associated Lymphoid Tissue	+	+	+	-	-	-	+/-	-	+	-	-	+			-	-	-	-	-	+	-	-	Low	-	
Lymphoplasmacytic Lymphoma	+	+	+	-	-	-	-	-	-	-	-	+								-	-	-	Low	-	
Diffuse Large B-cell Lymphoma	+	+	+	+	+	-	-	-	+	+	-	+			+				+	-	-	+/-	High	-	
Primary Mediastinal Large B-cell Lymphoma	+	+	+	+	-	+	-	+	+	+	-	+	+	+	+				-	-	No slg	-	-	-	
T-cell and Histiocyte Rich Large B-cell Lymphoma	+	+	+	-	-	-	-	-	-/+	+	-	+									-	-/+	High	-	
Intravascular Large B-cell Lymphoma	+	+	+	+	+	-	-	-	-	-	-	+			+ if CD10-							-/+	High	-	
ALK+ Large B-cell Lymphoma	-/+	-	-	-	-	-	-/+	-	-	-	-	-			+						-/+	-	-	ALK-1+	
EBV+ Large B-cell Lymphoma	+	+	+	-	-	-	-	-/+	-	-	-	-			+							+/-	-	-	+
Plasmablastic Lymphoma	-/+	-/+	+	-	-	-	-	+	-	-	-	-/+			+						clg, IgG	+/-	High	-	EBER+
Hairy Cell Leukemia	+	+	+	-	-	-	-	-	-	-	+	weak	+			+	+	+	+	-	+	-	-	-	
Primary Effusion Lymphoma	+	-	-	CD138+				+	-	-	-	-									No s/clg	-/+	-	-	+, HHV-8+
Burkitt Lymphoma	+	+	+	+	-	-	+	-	-	+	-	+			- or -/+					+	-	+	High	-/+	
B-cell Lymphoma, unclassifiable, with features intermediate between DLBCL and Burkitt Lymphoma	+	+	+	+					- or +	+	-	-			- or -/+							+	High	-/+	
B-cell Lymphoma, unclassifiable, with features intermediate between DLBCL and classical Hodgkin Lymphoma	+	+	+	-		-/+		+		+	-	+	+	+							No s/clg	-	-	-	
HHV-8+ DLBCL	+	+/-	-	CD138-																		-/+	-	-	-, HHV-8+

Mature T-Cell Lymphomas	CD2	CD3	CD4	CD5	CD7	CD8	CD25	CD30	CD56	CD57	CD10	BCL6	EMA	Granzyme B	TIA-1	Perforin	EBV
T-cell Prolymphocytic Leukemia	+	+	+	+	+	+/-	-	-	-	-	-	-	-	-	-	-	-
T-cell Large Granular Lymphocytic Leukemia	+	+	-	-/+	-/+	+	-	-	-	+	-	-	-	+	+	+	-
Adult T-cell Leukemia/Lymphoma	+	+	+	+	-	+	-/+	-	-	-	-	-	-	-	-	-	-
Peripheral T-cell Lymphoma, not otherwise specified	+	+	+/-	-/+	-/+	-/+	-	-/+	-	-	-	-	-	-	-	-	-
Angioimmunoblastic T-cell Lymphoma	+	+	+	+	+	-	-	-	-	-	+/-	+/-	-	-	-	-	-
Anaplastic Large Cell Lymphoma, ALK+	+/-	-/+	+/-	+/-	-/+	-/+	+	+	+/-	-	-	+	+	+	+	+	-
Anaplastic Large Cell Lymphoma, ALK-	+/-	+/-	+/-	+/-	-/+	-/+	+	+	+/-	-	-	-	+	+/-	+/-	+/-	-
Hepatosplenic T-cell Lymphoma	+	+	-	-	+	+/-	-	-	+	-	-	-	-	+	+	+	-
Subcutaneous Panniculitis-like T-cell Lymphoma	+	+	-	-/+	+	+	-	-	+	-	-	-	-	+	+	+	-
Enteropathy-associated T-cell Lymphoma	+	+	-	-	+	-/+	-/+	-/+	-/+	-	-	-	-/+	+	+	+	-
Extranodal NK/T-cell Lymphoma, Nasal Type	+	+, cyto	-	-	-	-/+	-	-	+	-	-	-	-	+	+	+	+
AggNKL	+	+, cyto	-	-	-	-/+	-	-	+	-	-	-	-	+	+	+	+
PCyTCL	+	+	-	-/+	-/+	-/+	-	-	+	-	-	-	-	-	+	+	-
PCCD30+TLPD	+	+	+	+/-	-	-	+	+	-	-	-	-	+/-	+	+	+	-
MF/SS	+	+	+	+/-	-/+	-/+	-	-	-	-	-	-	-	-	-	-	-

Cell Marque strives to be complete and accurate in the presentation of this information; however, Cell Marque, its shareholders, its officers, its employees, and its business associates assume no liability for any reliance on any of the contents of this poster including but not limited to any of the antibody panels without regard to whether or not these are accurate and/or complete. Furthermore, Cell Marque assumes no liability for any omissions. It is the sole responsibility of laboratories to independently validate the application and proper use of any product(s) and/or protocols. Cell Marque reserves the right to make any changes, additions, and/or deletions to its product offerings at any time without notice. The antibody panels were constructed based on Cell Marque's internal investigations with scores based on the percentage of positivity represented as follows: "+" for 0-40%, "-/+ for 40-50%, "+/+ for 50-60%, "+" for 60-100%, and blank for no available data.

©2015 Sigma-Aldrich Co. LLC. All rights reserved. SIGMA-ALDRICH and Cell Marque are trademarks of Sigma-Aldrich Co.

Hodgkin Lymphomas and Differential Diagnosis	CD30	CD15	CD45	CD20	CD79a	PAX-5	Oct-2	BOB.1	CD3	CD2	CD43	Granzyme B	Perforin	TIA-1	EMA	ALK	LMP	EBER	IMP3	
Classical Hodgkin Lymphoma	+	+/-	-	-/+	-/+	+	-/+	-	-	-	-	-	-	-	-	-	-	+/-	+/-	+
Nodular Lymphocyte Predominant Hodgkin Lymphoma	-	-	+	+	+	+	+	+	-	-	-	-	-	-	+/-	-	-	-	-	+
T-cell Rich Large B-Cell Lymphoma	-	-	+	+	+	+	+	+	-	-	-	-	-	-	+/-	-	-	-	-	+
Diffuse Large B-cell Lymphoma	-/+	-	+	+	+	+	+	+	-	-	-/+	-	-	-	-/+	-	-/+	-/+	+	
Anaplastic Large Cell Lymphoma, ALK+	+	-	+/-	-	-	-	-	-	-/+	-/+	+/-	+	+	+	+	+	-	-	-	
Anaplastic Large Cell Lymphoma, ALK-	+	-	+/-	-	-	-	-	-	-/+	+/-	+/-	+	+	+	+	-	-	-	-	

Acute Myeloid Leukemia and Related Neoplasms	TdT	CD34	HLA-DR	CD13	CD33	CD2	CD15	CD19	CD4	CD14	CD41	CD61	CD71	CD68 (KP1)	CD56	CD117	CD163	Glycophorin A	Hgb A	MPO
AML with t(8;21)	-/+ weak	+	+	+	+ weak	-	+	+	-	-	-	-	-	-	-/+	-	-	-	-	+
AML with inv(16) or t(16;16)	-	+	+	+	+	+	+	-	+	-	-	-	-	+	-	+	-	-	-	+
AML with t(15;17)	-	-/+	-/+	+	+	-	-	-	-	-	-	-	-	-	+	+	-	-	-	+
AML with t(9;11)	-	-/+	+	+ weak	-	-	-	-	+	+ weak	-	-	-	+	+ weak	+ weak	-	-	-	-
AML with t(6;9)	+	+	+	+	+	-	+	-	-	-	-	-	-	-	-	+	-	-	-	+
AML with inv(3) or t(3;3)	-	+	+	+	+	CD7 +/-					+ subset	+ subset								
AML with t(1;22)	-	-	-	-/+	-/+	-	-	-	-	+	+	-	-	-	-	-	-	-	-	-
AML with mutated NPM1	-	-	+	+	+	-	-	-	+	-	-	-	-	+	-	-	-	-	-	+
AML with mutated CEBPA	-	+	+	+	+	CD7+	+													
AML with dysplasia-related changes	-/+	-/+		+	+	CD7, -/+										-/+				
AML with minimal differentiation	+	+	+	+	+	CD7+	-	-	-	-	-	-	-	-	-	+	-	-	-	-
AML without maturation	-	+	+	+	+	+	-	+	+	-	-	-	-	CD7+	+	+	-	-	-	+
AML with maturation	-	+	+	+	+	+	+	+	+	-	-	-	-	CD7+	+	+	-	-	-	+
Acute Myelomonocytic Leukemia	-	+	+	+	+	CD7+	+	+	+	-	-	-	-	+	-	+	+	-	-	+
Acute Monoblastic and Monocytic Leukemia	-	+	+	+	+	CD7+	+	-	+	+	-	-	-	+	+	+	+	-	-	-
Acute Erythroid Leukemia	-	-	-	-	-	-	-	-	-	-	-	-	+/-	-	-	+/-	-	+	+	-
Acute Megakaryoblastic Leukemia	-	-	-	-/+	-/+	+								-	CD7+	-	-	-	-	-
Myeloid Sarcoma	+	+							+	+	+	+	+	+	+	+	+	+	+	+